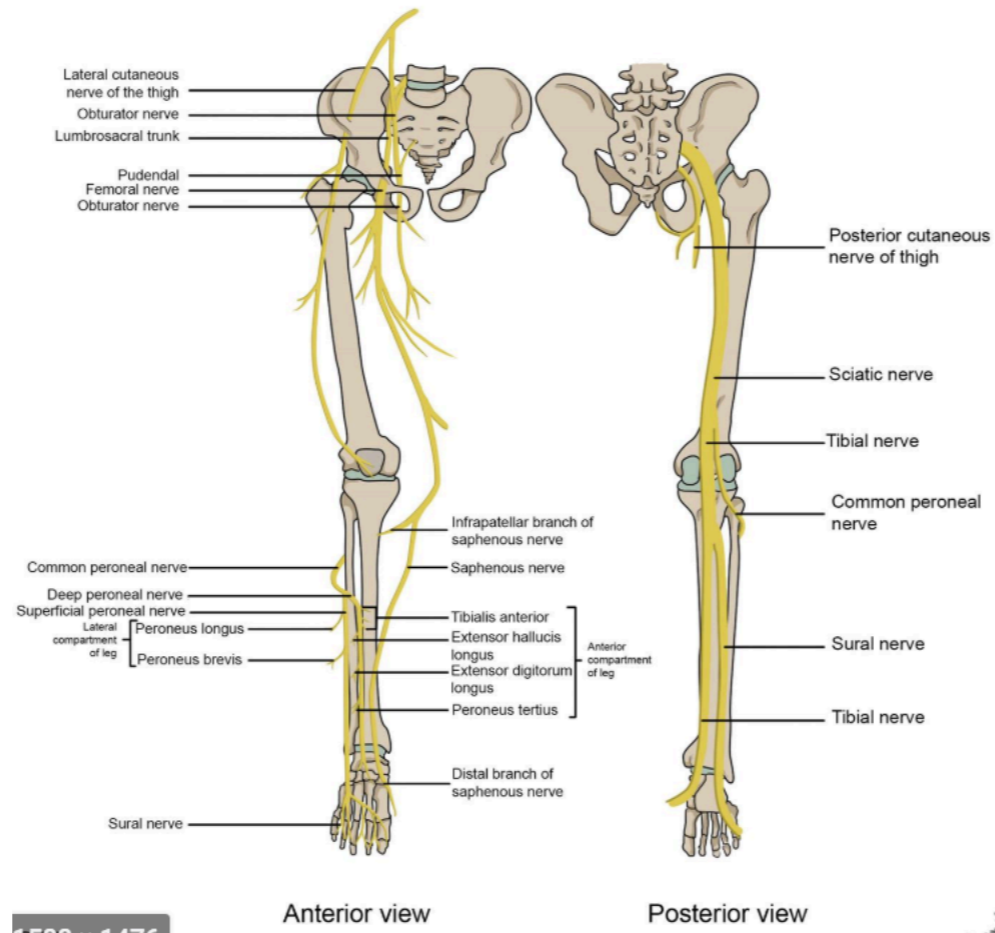
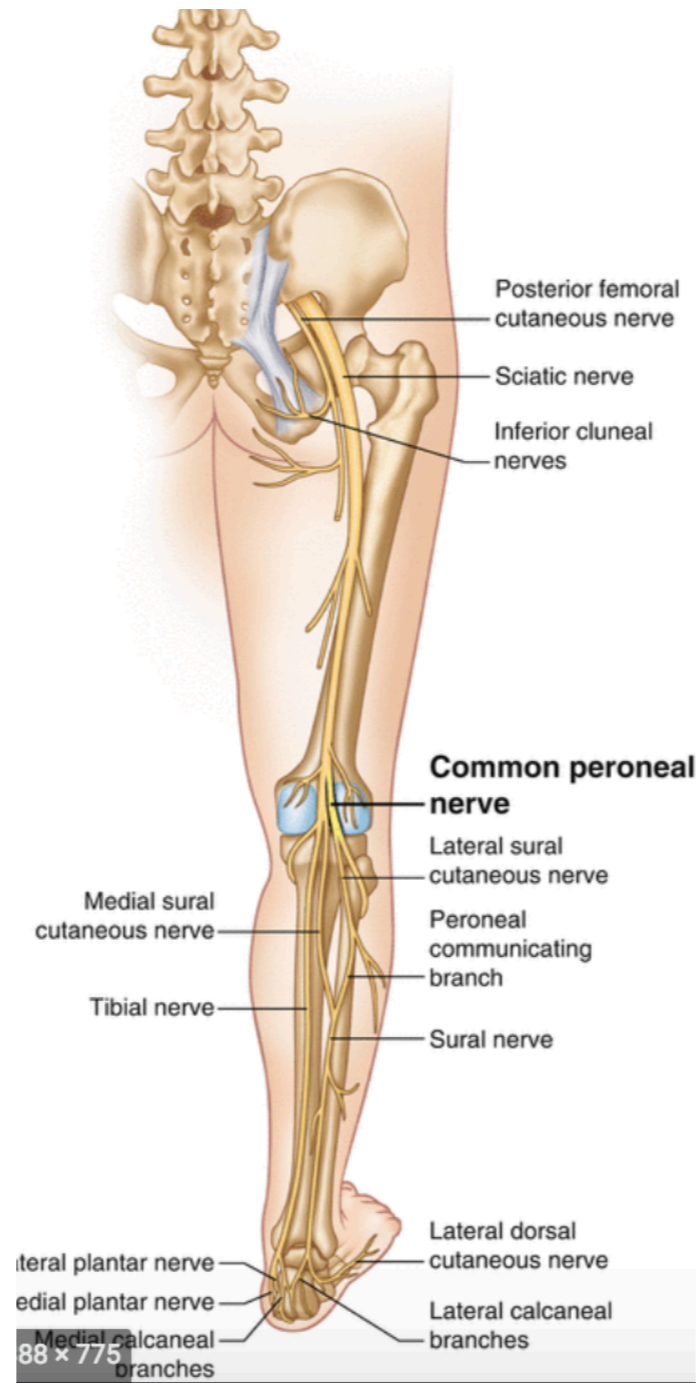


Nerves of the Lower Extremities

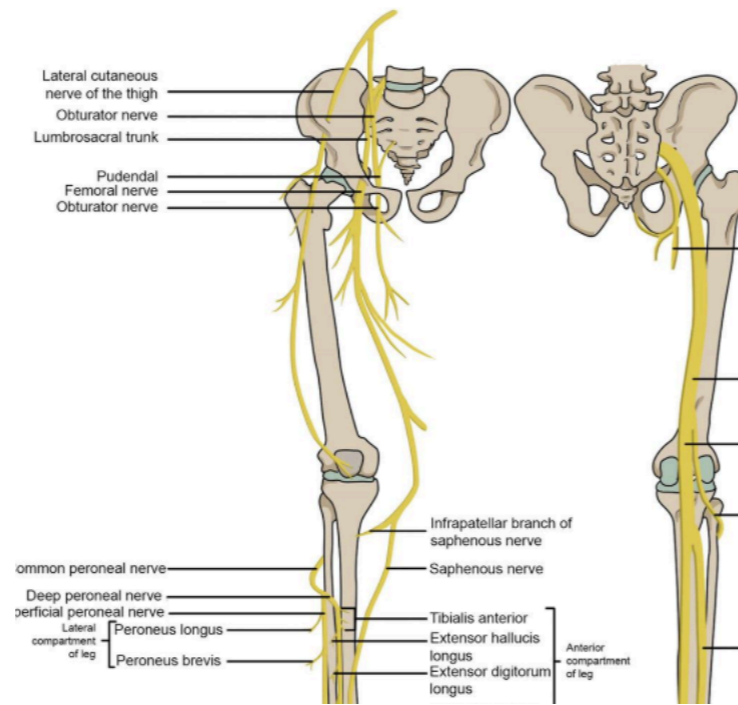


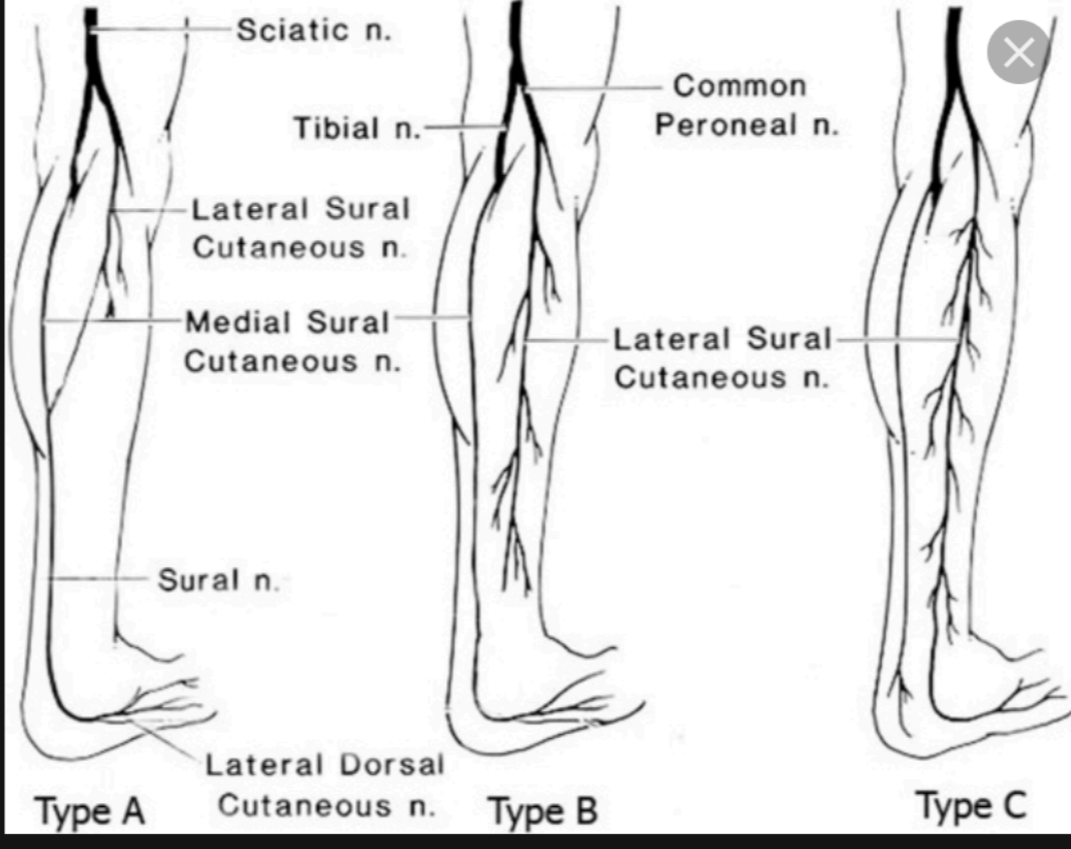


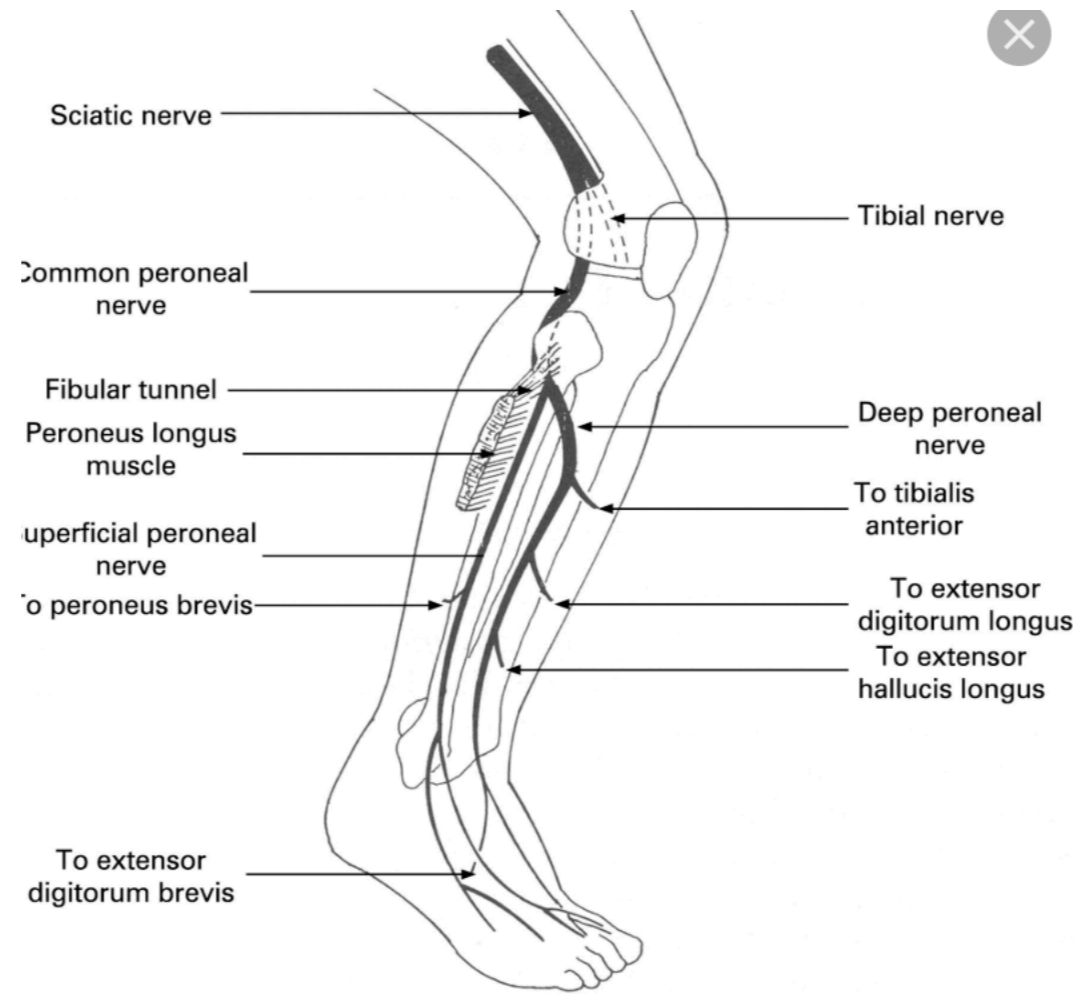
88 x 775

tibia nerve

NERVES OF THE LOWER EXTREMITY

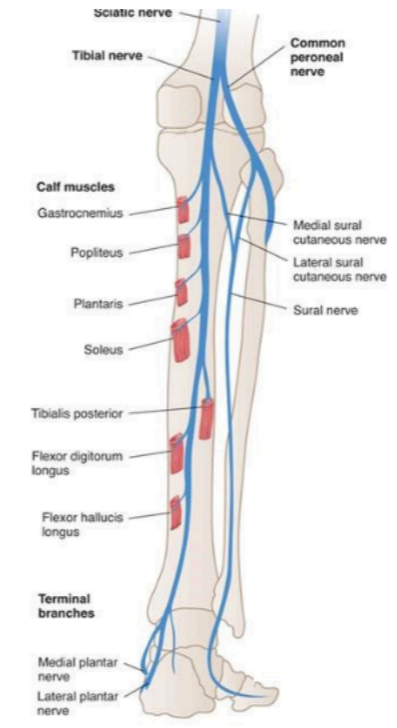
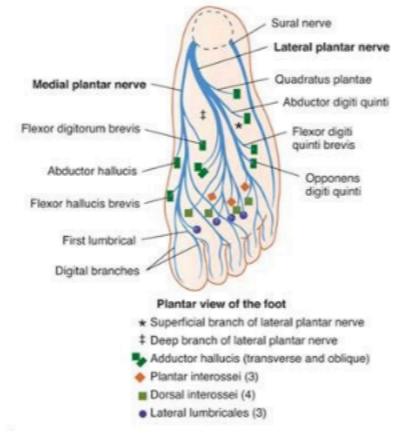



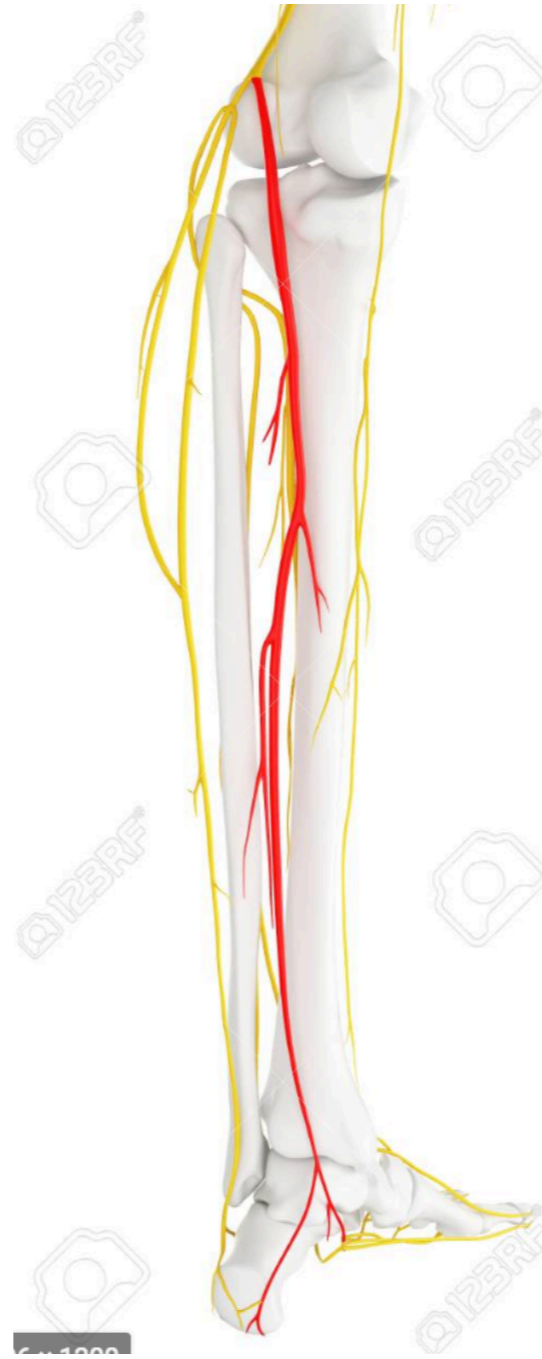


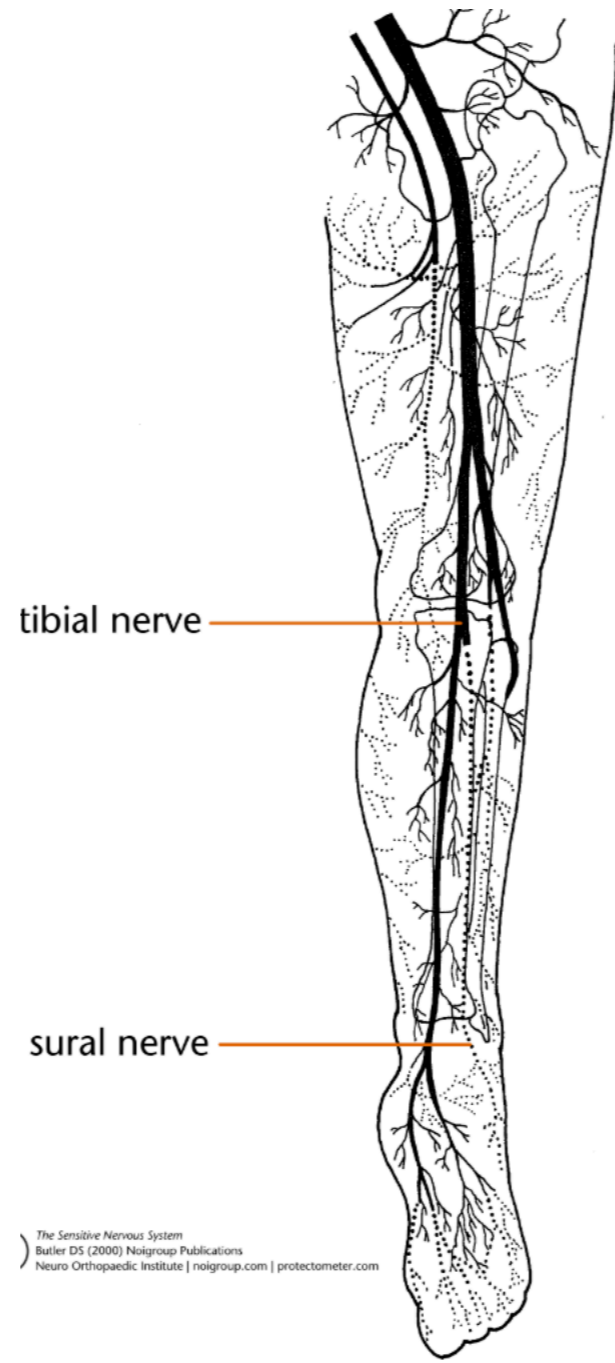
The Tibial Nerve

- Motor functions
 - Foot plantar flexion and inversion, toe flexion



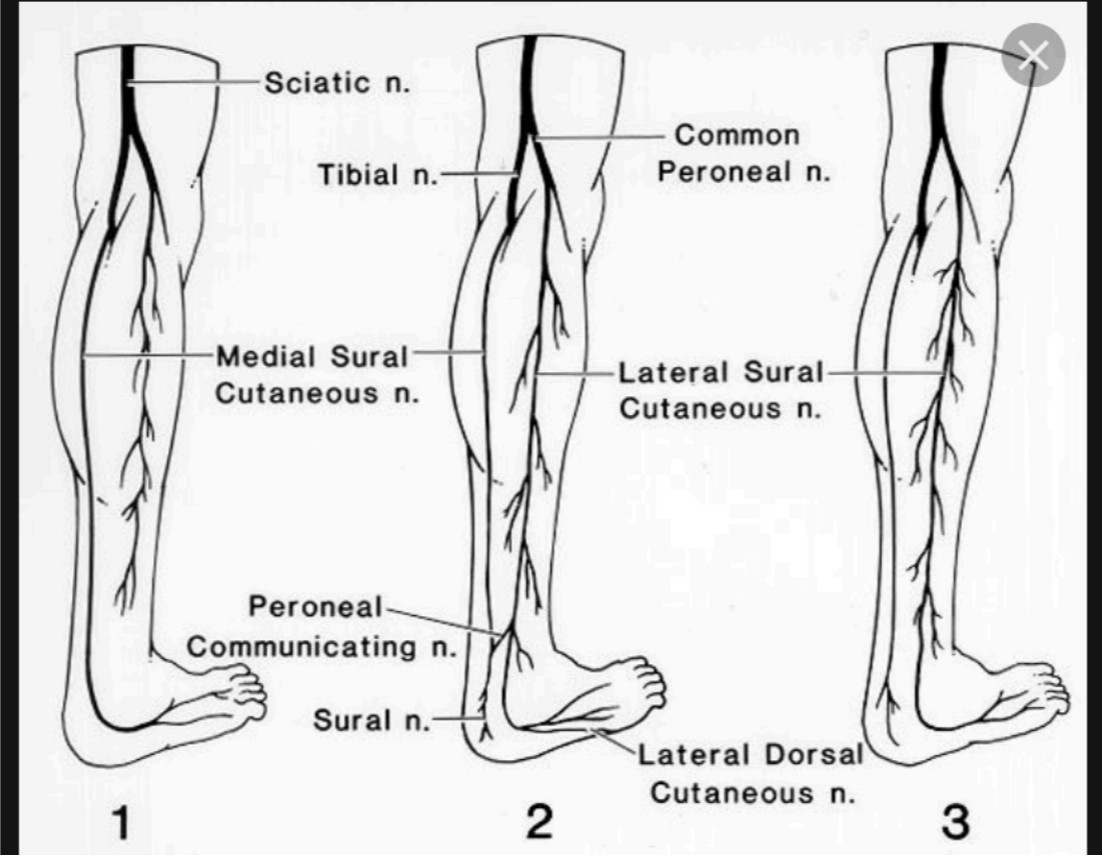
sural nerve



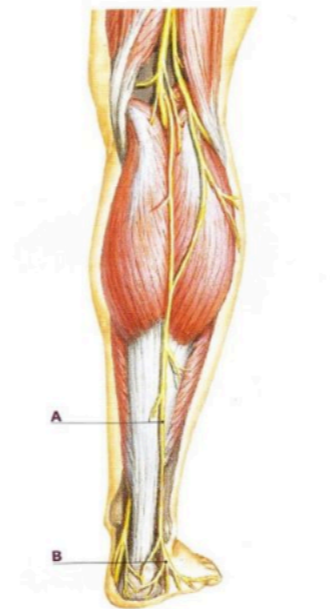

tibial nerve

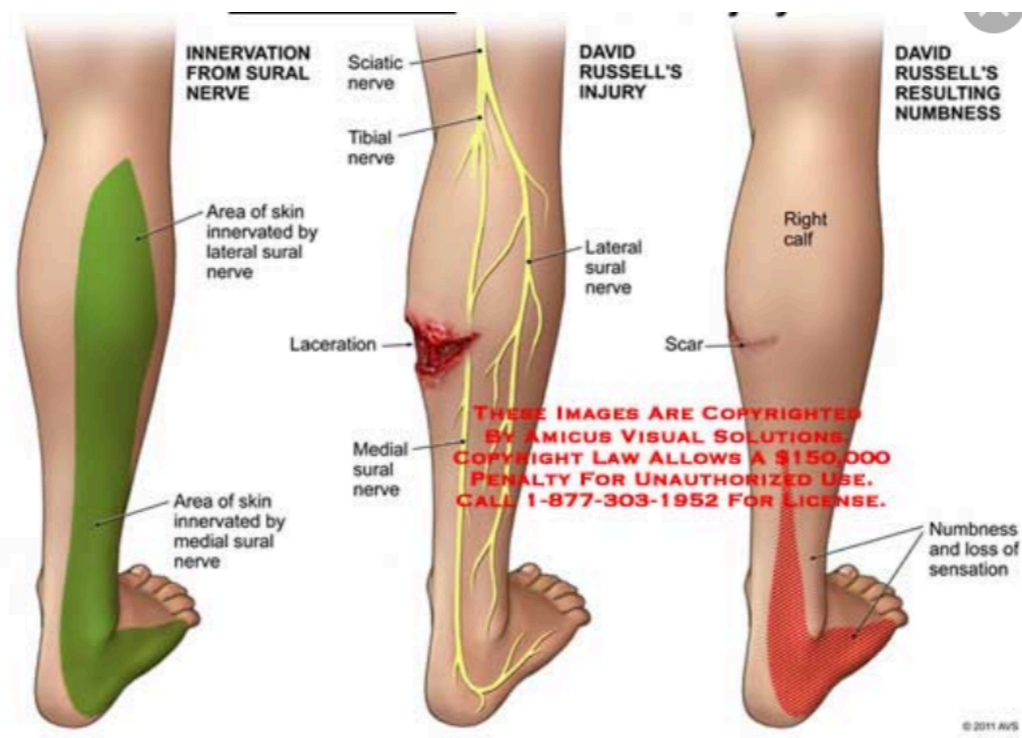
sural nerve



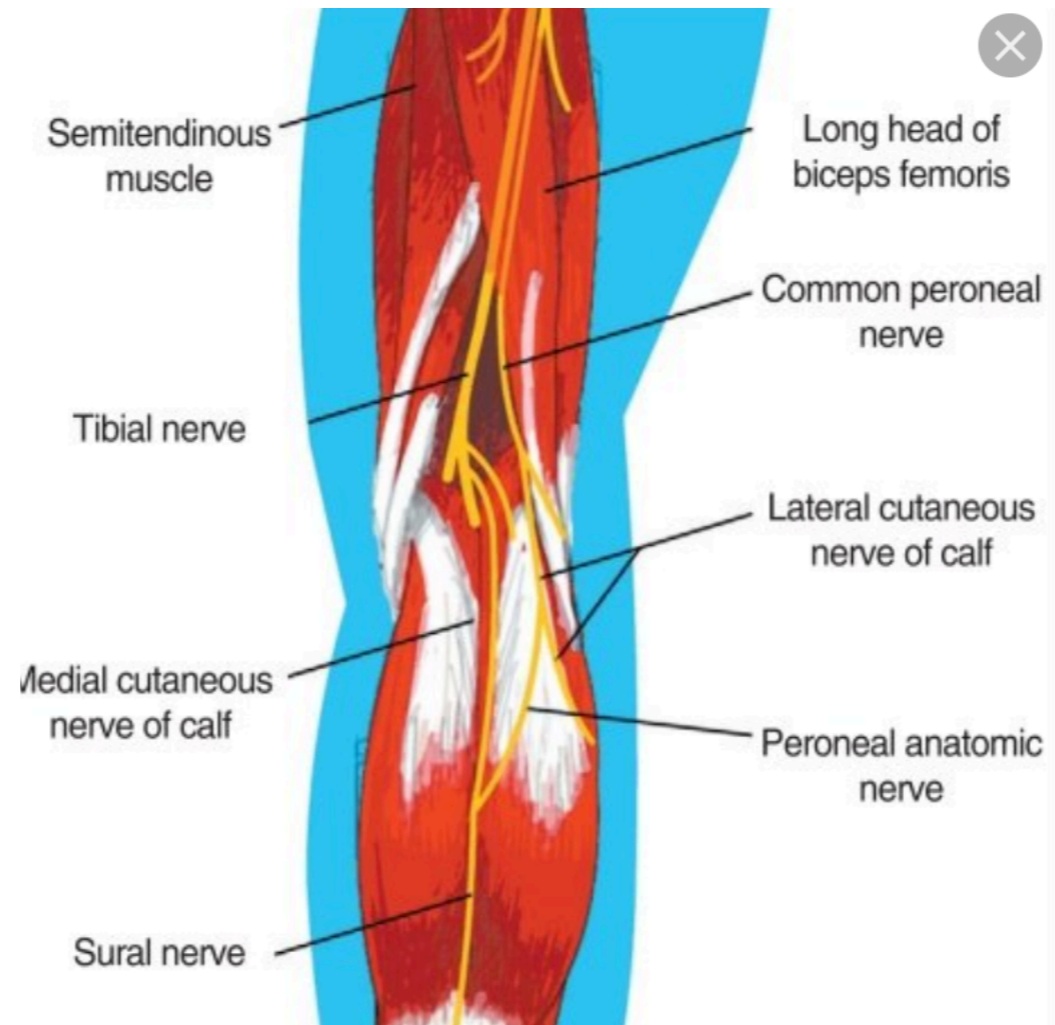
Sural Nerve

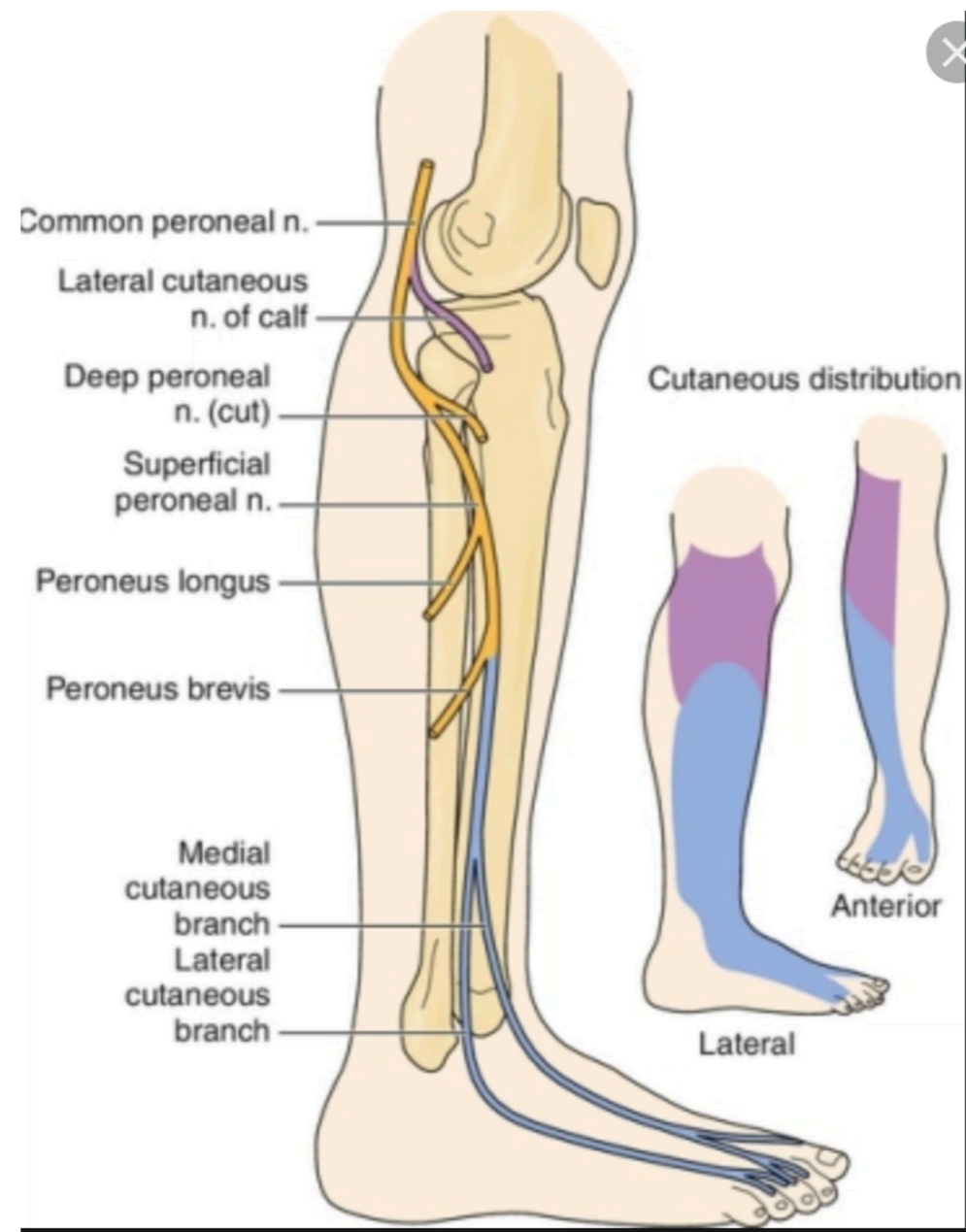


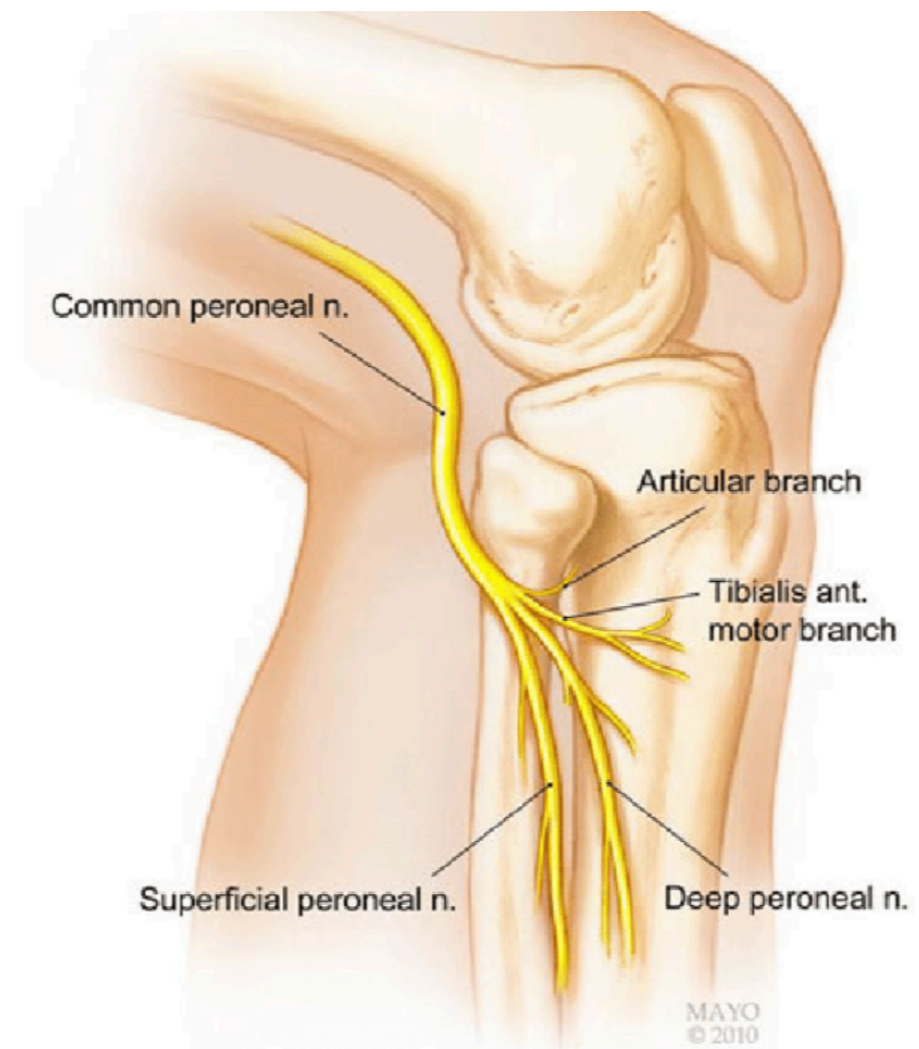
WWW.PHYSIO1ST.CO.UK

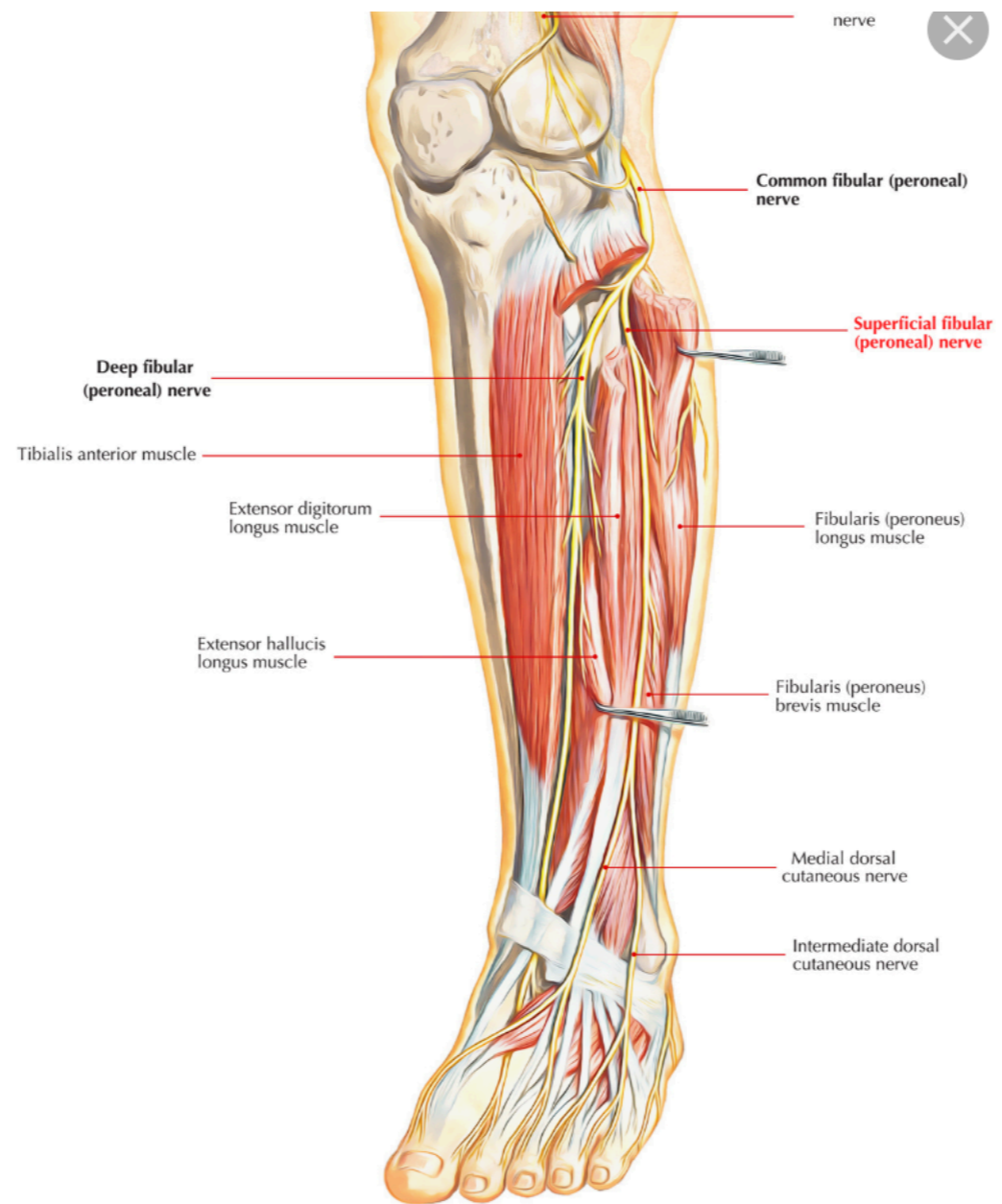


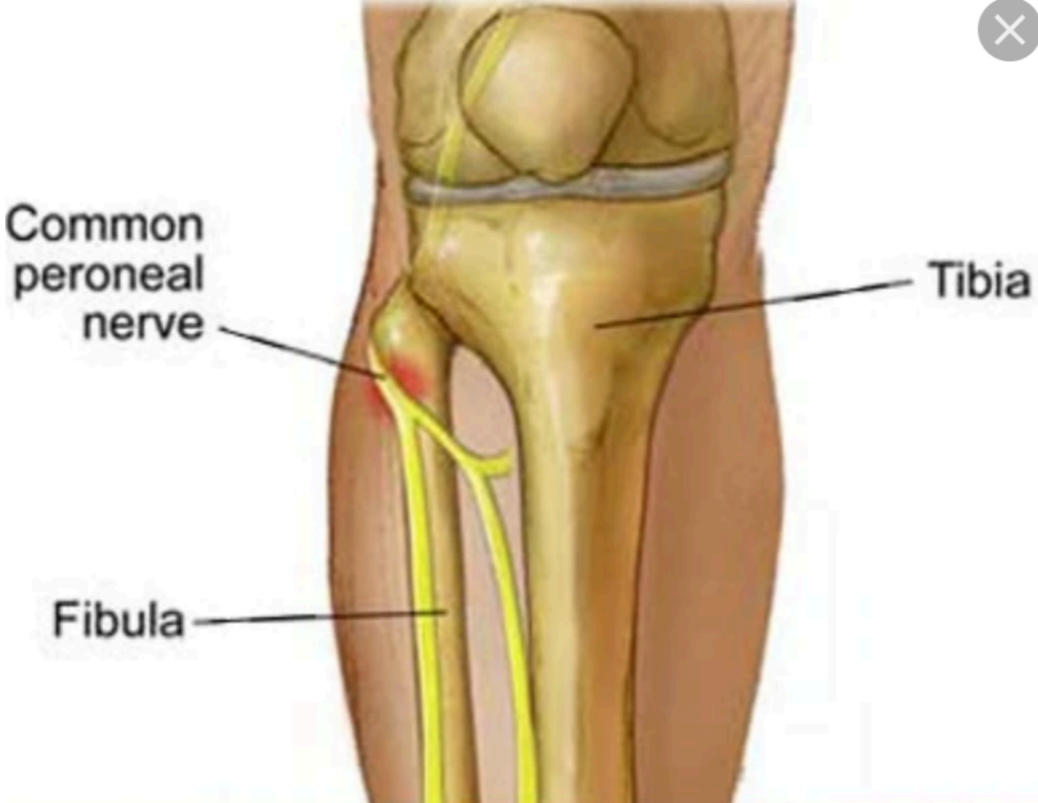peroneal nerve

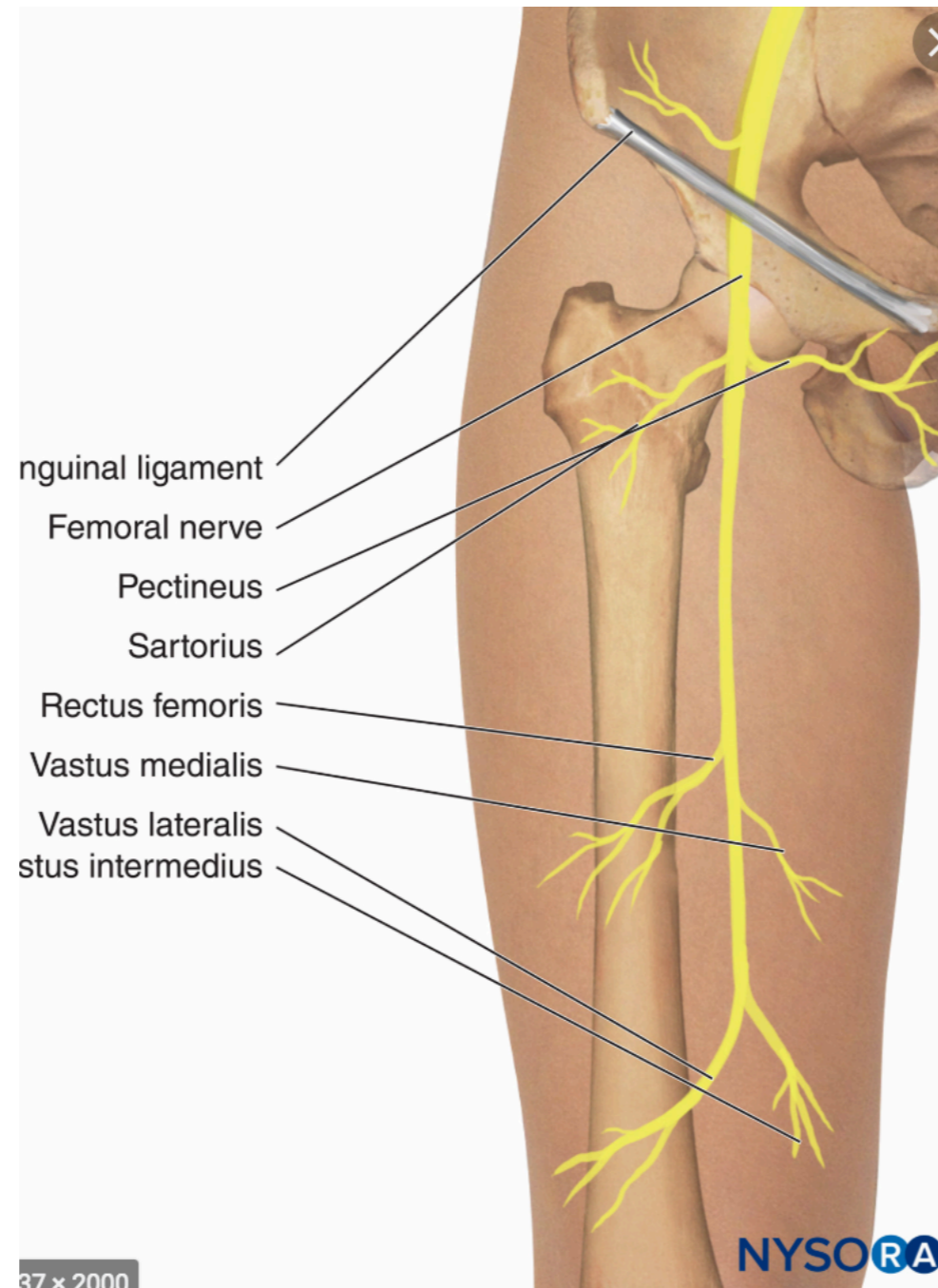


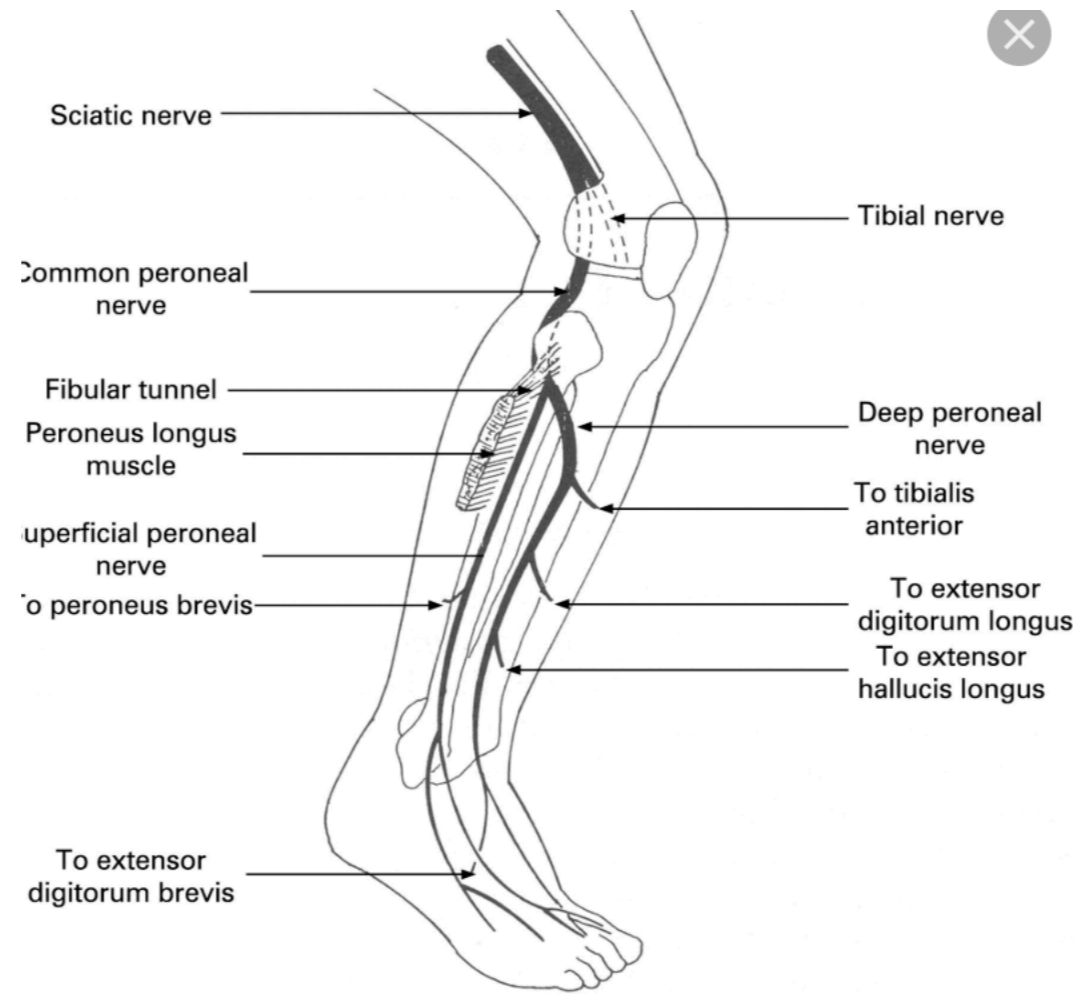




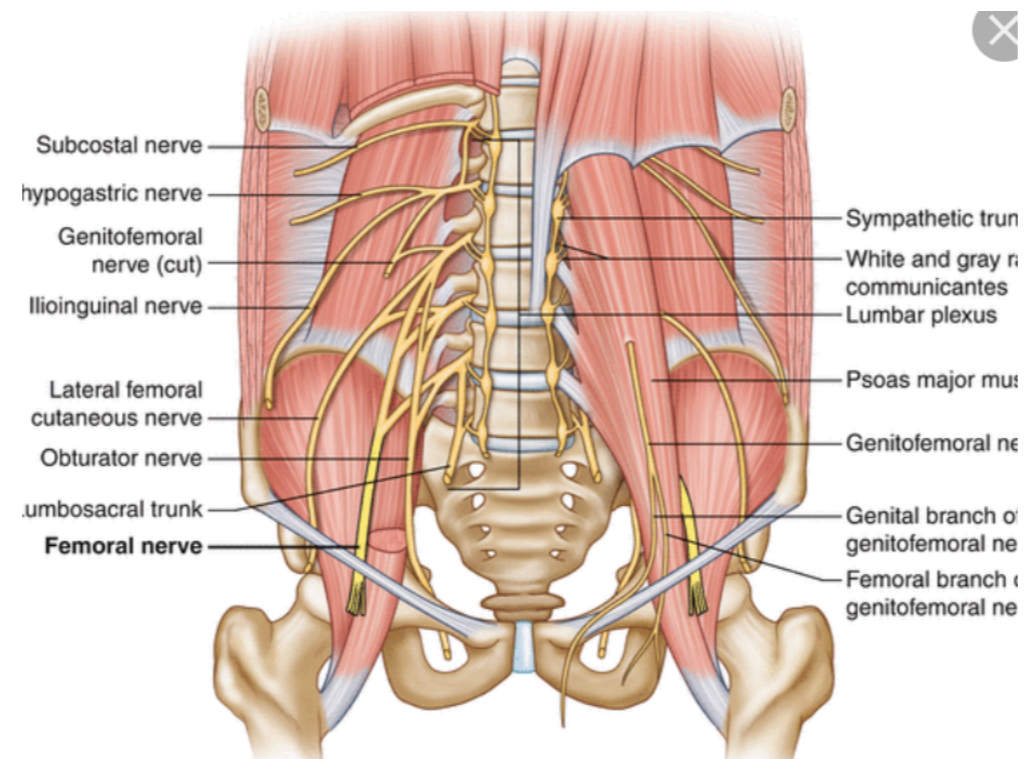








femoral nerve



Femoral and Obturator Nerves

- Femoral nerve
 - Motor functions
 - Leg flexion at the hip, leg extension at the knee
- Obturator nerve
 - Motor functions
 - Adduction of the thigh

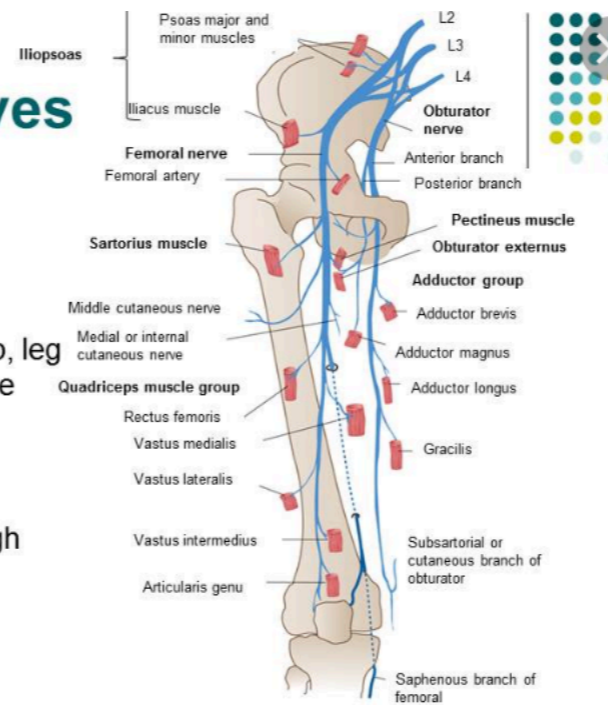
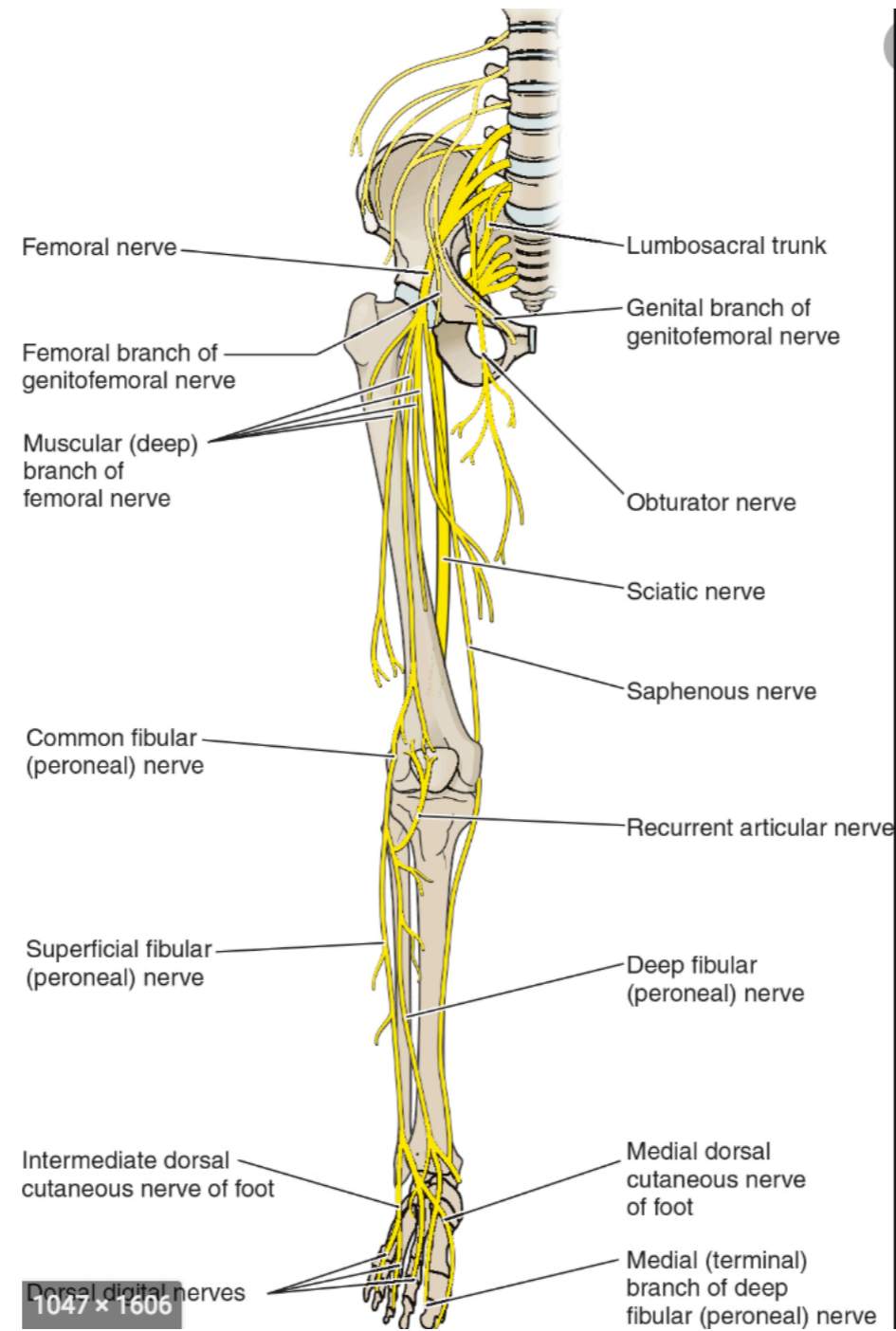
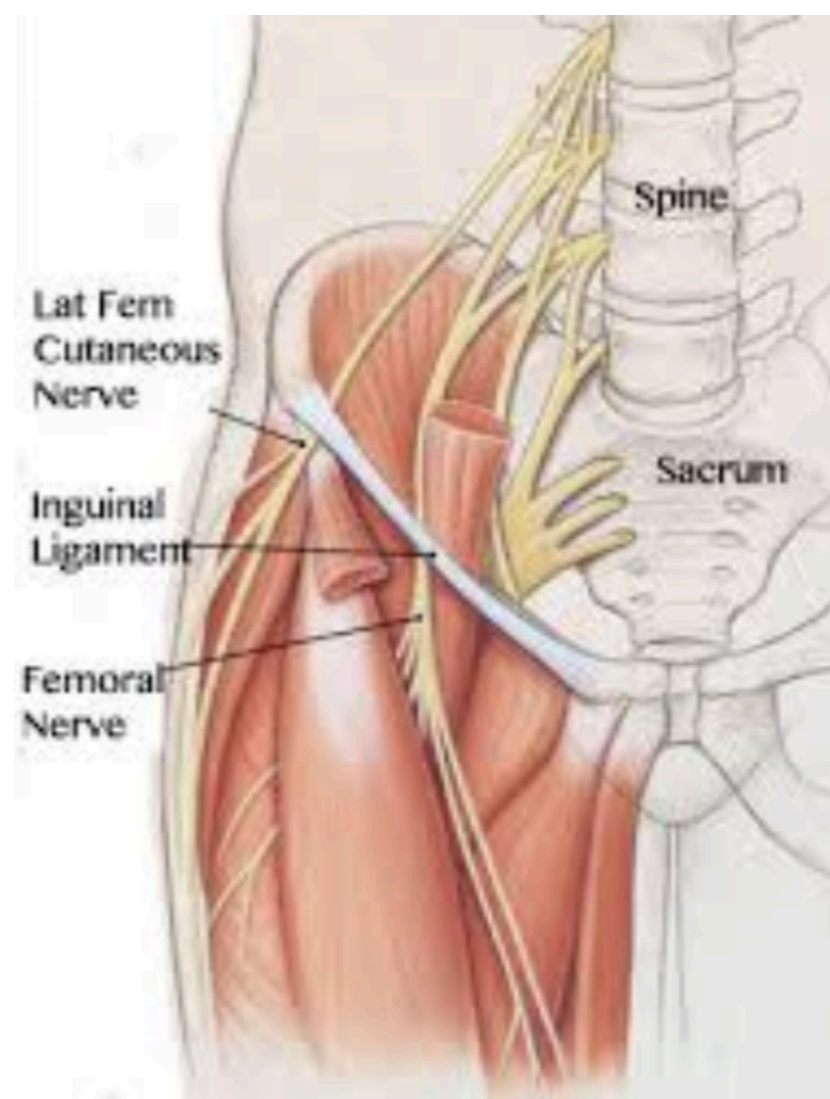


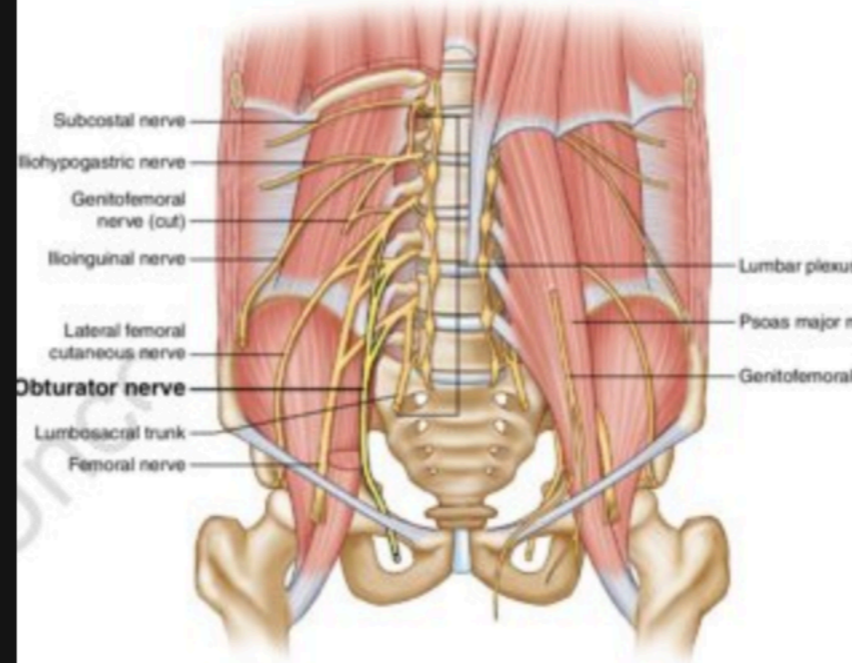
Figure 28-11 .The femoral and obturator nerves. In: Waxman SG. *Clinical Neuroanatomy*. 26th ed. New York, NY: McGraw-Hill; 2010. <http://www.accessphysiotherapy.com>. Accessed March 22, 2012.

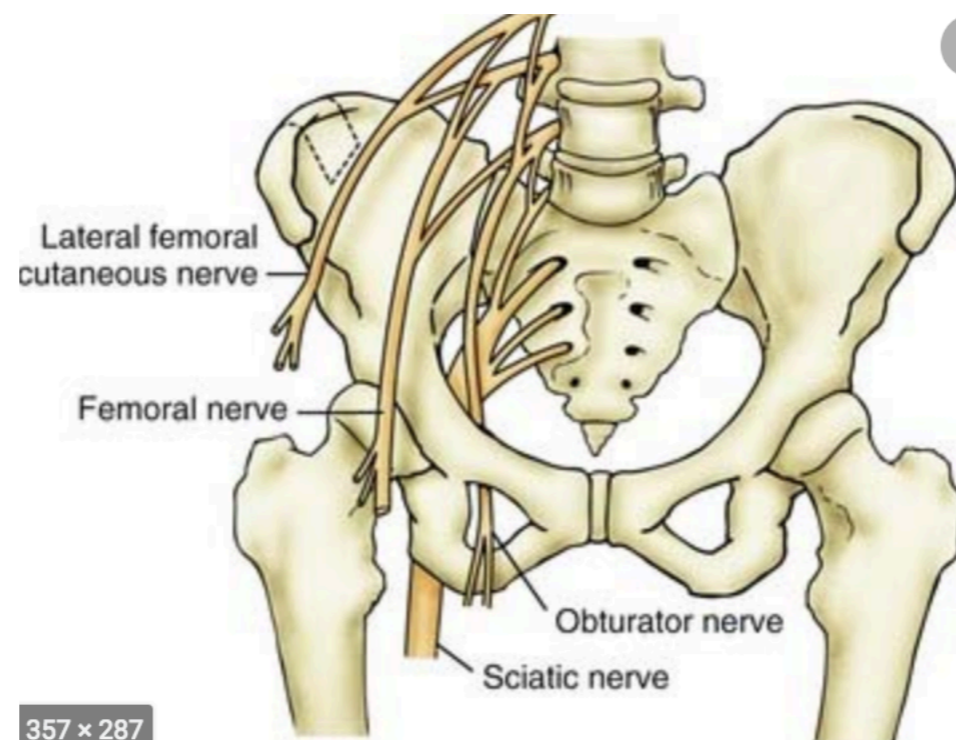


1047 x 1606



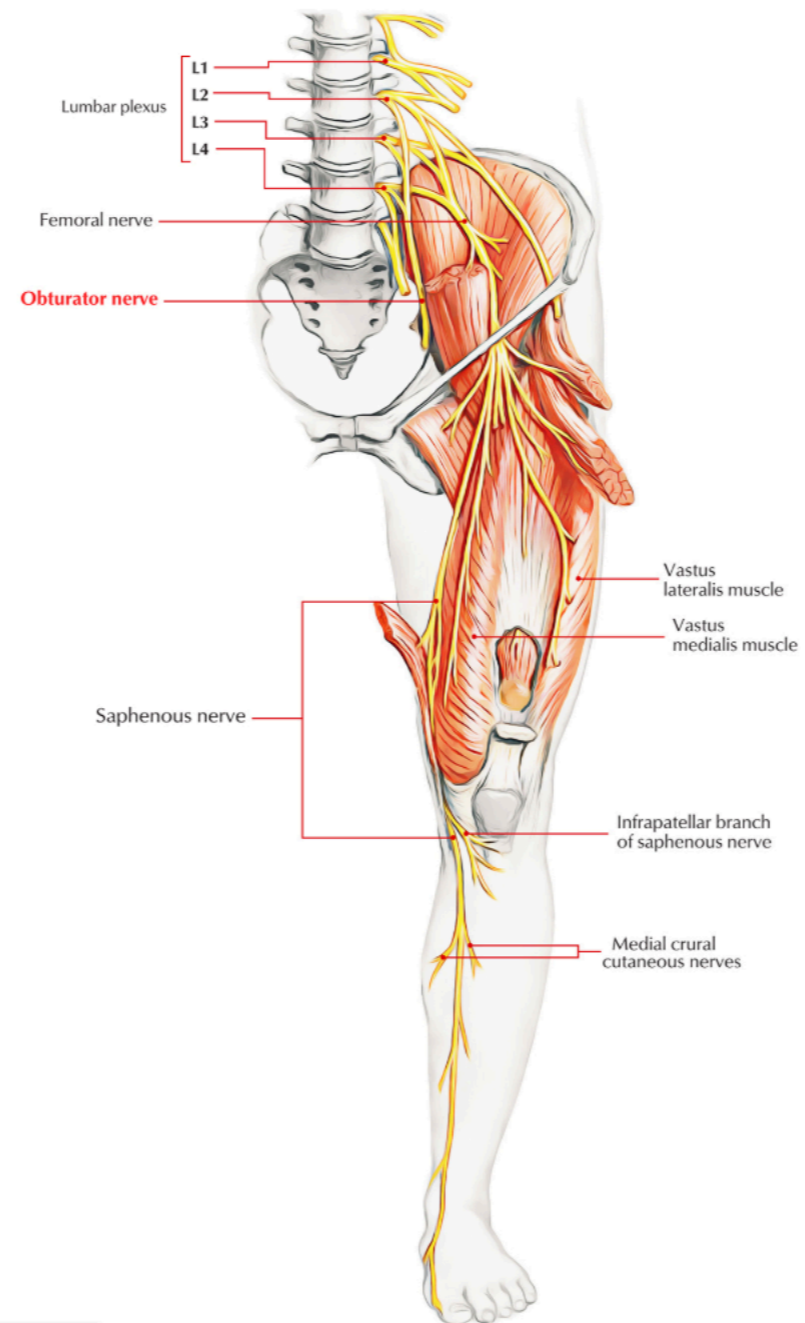
er division: adductor magnus (also gets motor from sciatic)
e adductor brevis is innervated solely by ON
ound n the triangle formed by the lower border of the superior pubic ramus, posterior pectineus, and
surface of obturator externus [27]





357 x 287

obturator nerve

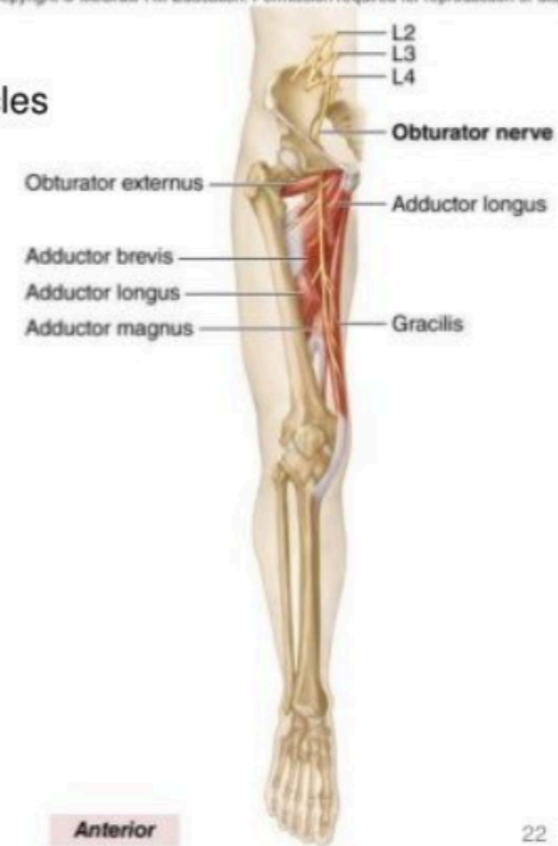

Lumbar Plexus – Obturator Nerve

Copyright © McGraw-Hill Education. Permission required for reproduction or display.

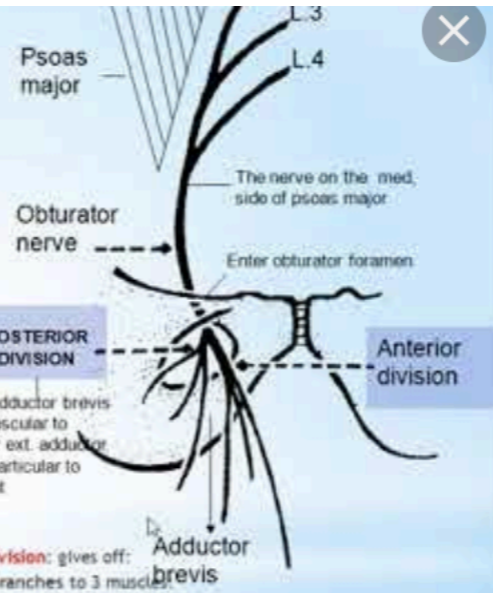
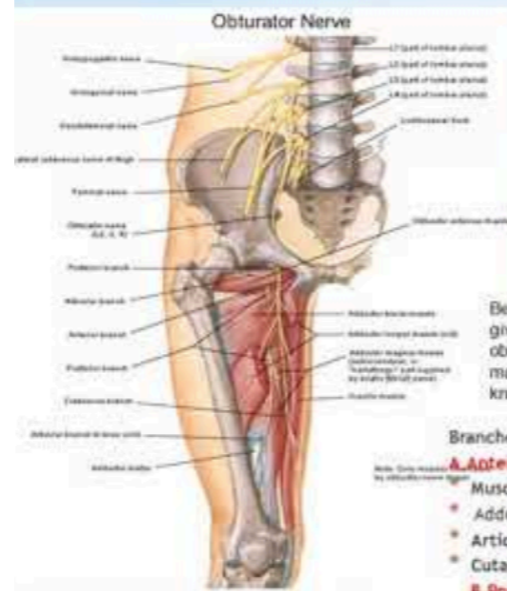- **Obturator nerve**

- Innervation: Medial thigh muscles
 - Gracilis
 - Adductor longus
 - Adductor brevis
 - Adductor magnus
 - Pectineus



38 x 479 5

Obturator nerve



Branches:

A. Anterior division: gives off:

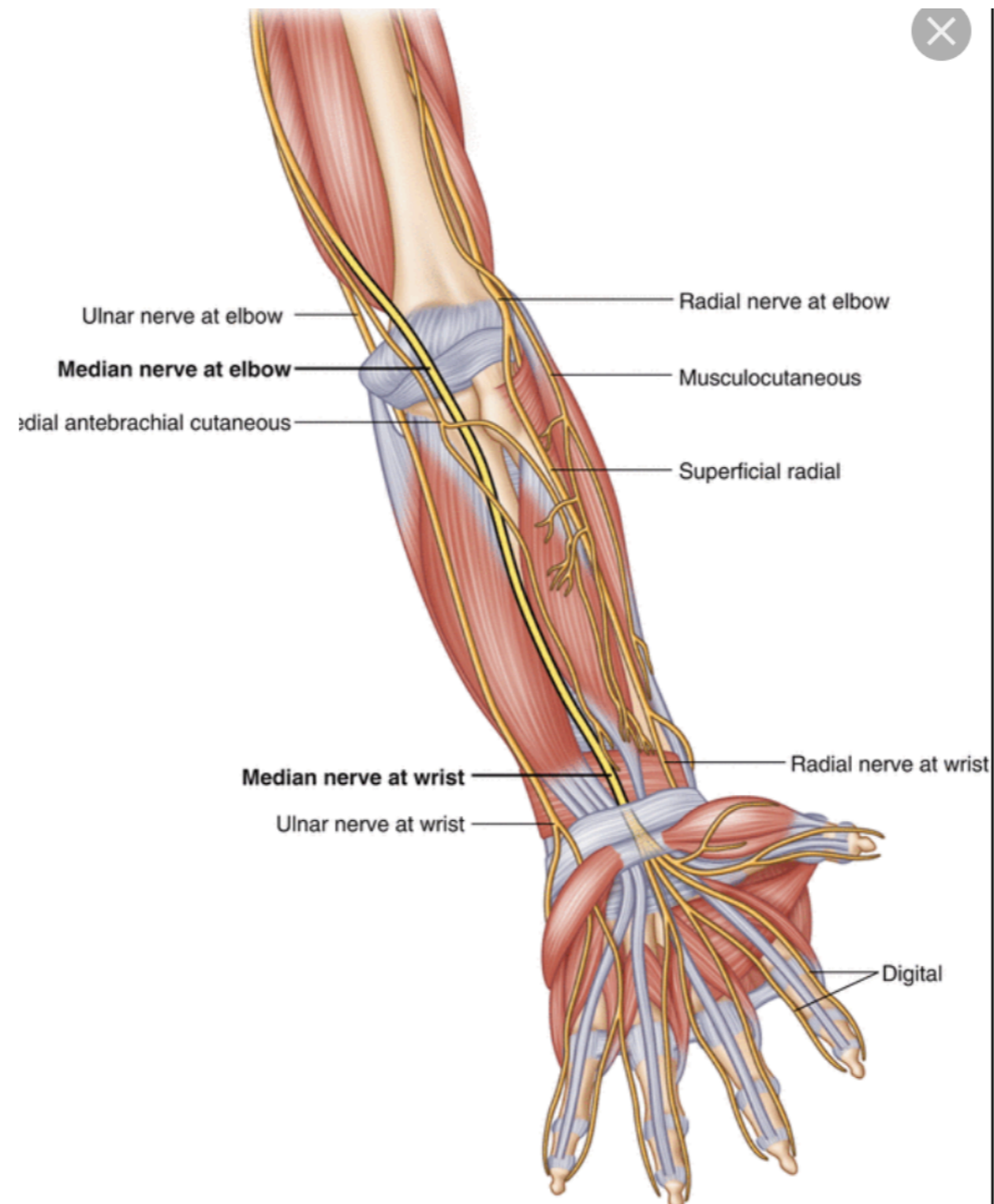
- Muscular branches to 3 muscles
- Adductor longus, adductor brevis & gracilis.
- Articular branch to the hip joint.
- Cutaneous branch to the skin of the medial side of the thigh.

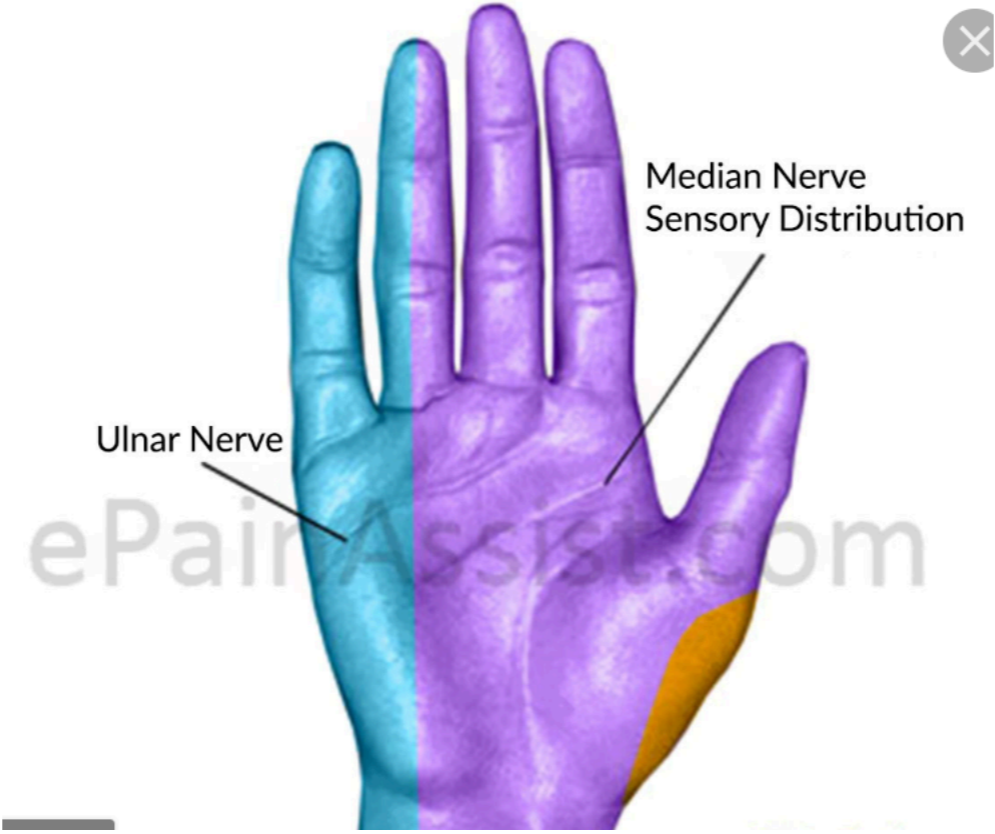
B. Posterior division: gives off:

- Muscular branches to 2 muscles:
- Obturator externus & adductor magnus (pubic part).
- Articular branch to the knee joint.

480 x 360

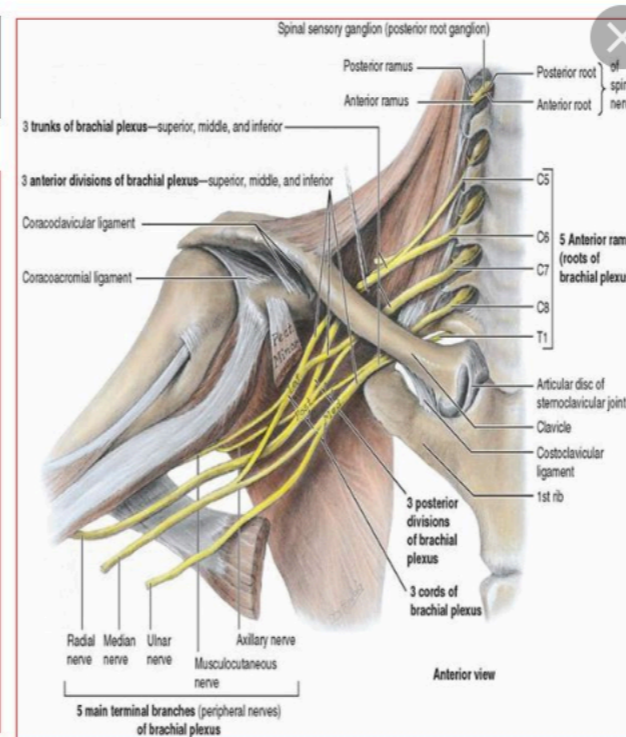
median nerve



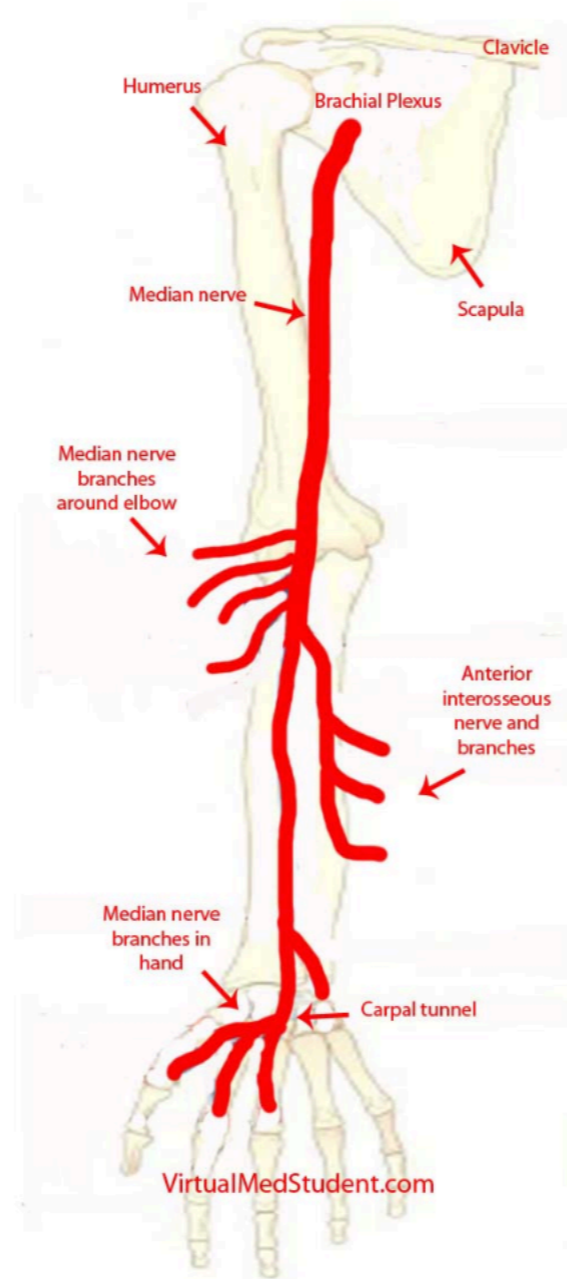


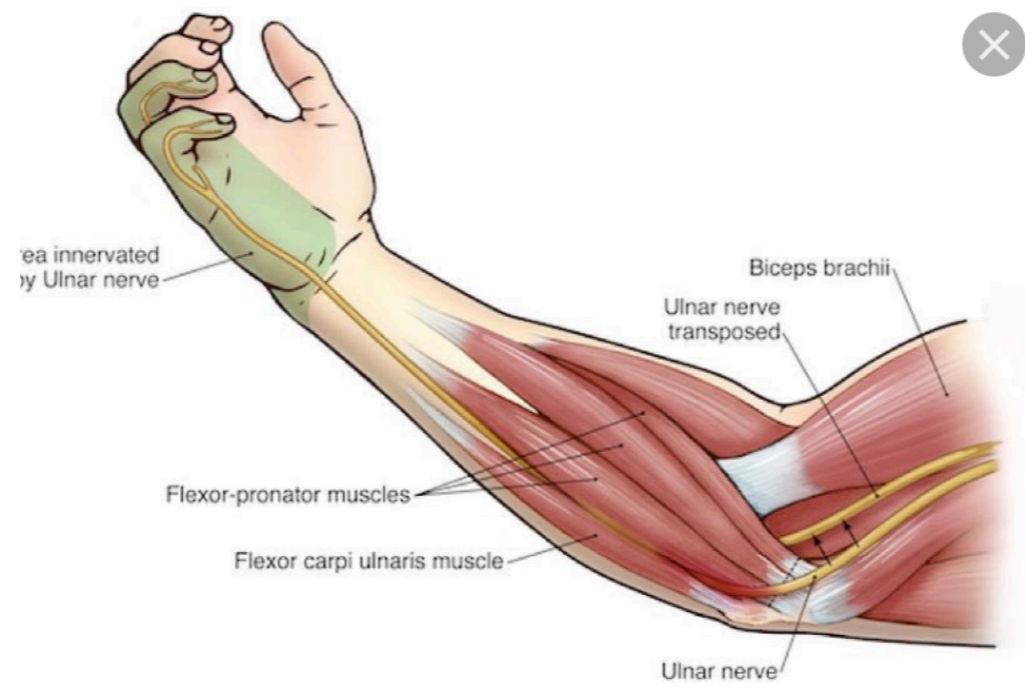
Median Nerve

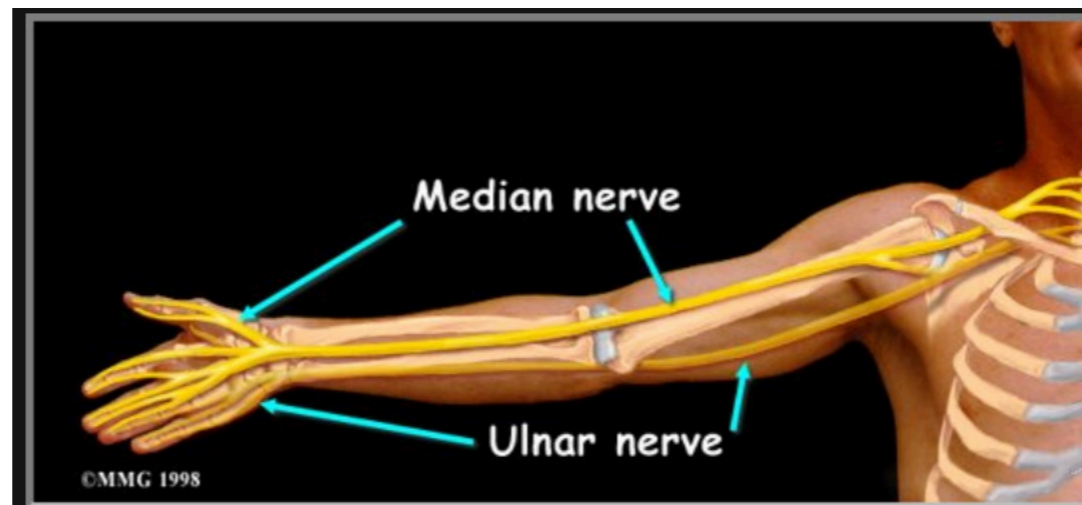
- **Origin:(C5,6,7, 8, T1)**
- The median nerve is formed **latera to the third part of the axillary artery.**
- **It is formed** by the union of the lateral and medial roots originating from the lateral and medial cords **of the brachial plexus respectively.**



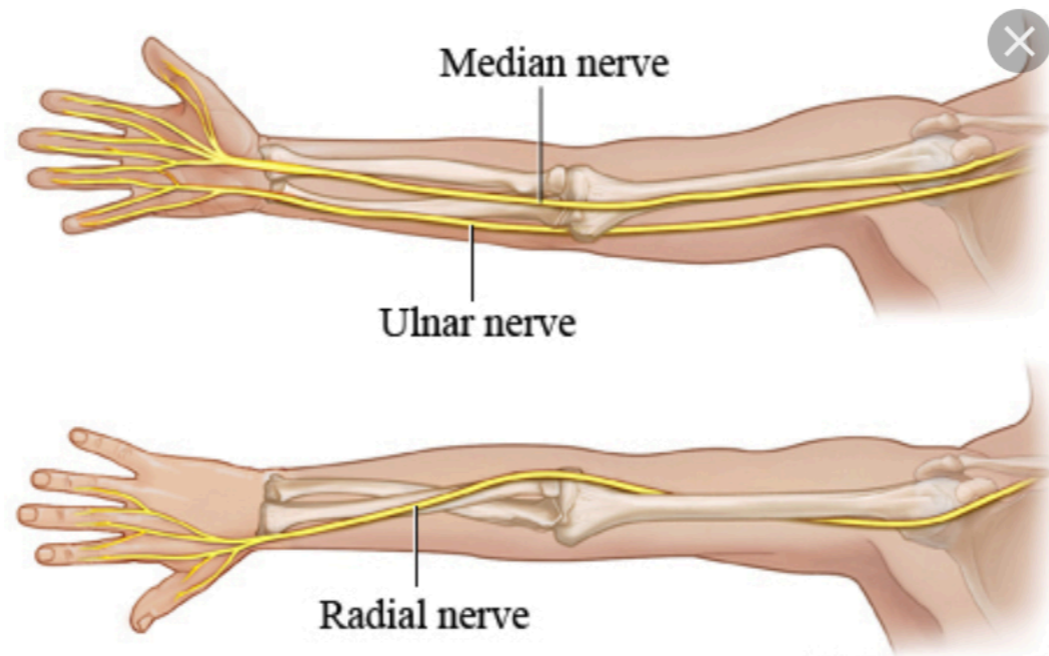
Median Nerve Anatomy

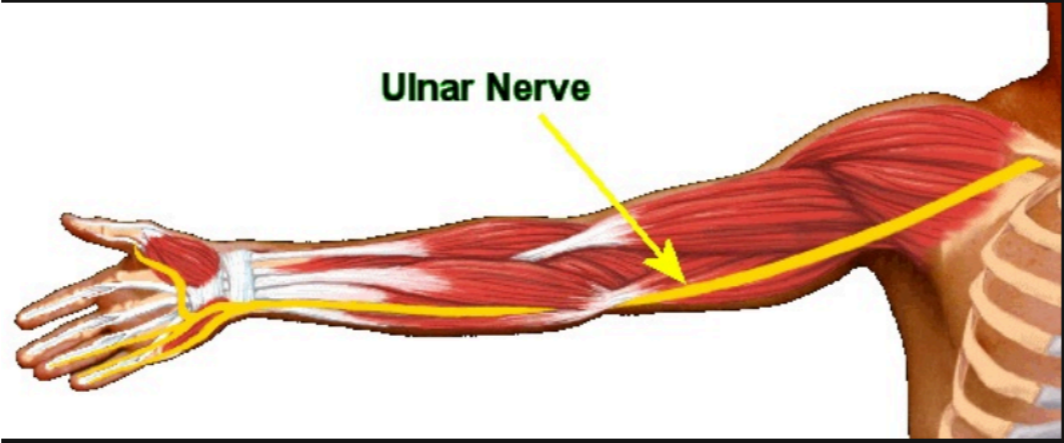


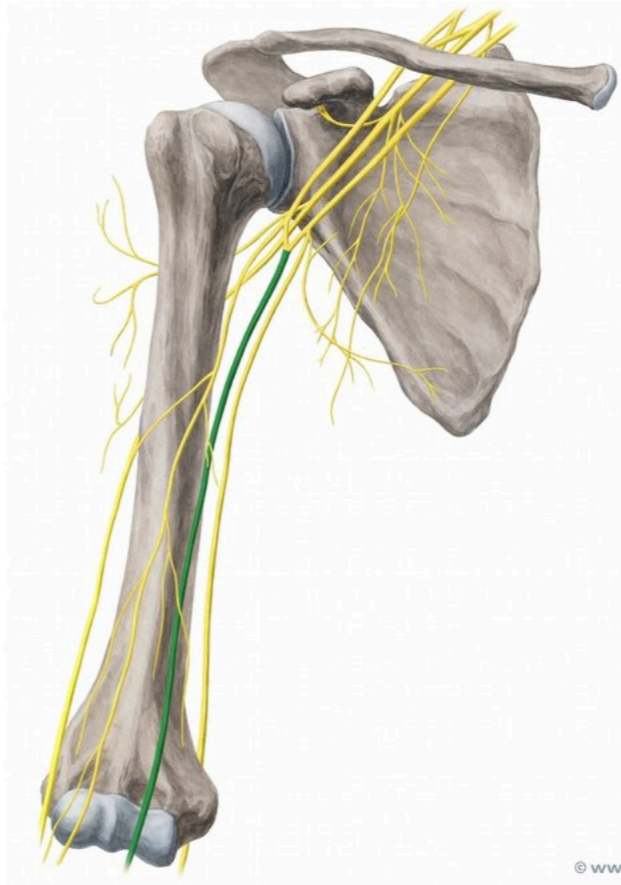




ulnar nerve







× 680

© www.kenhub.com

