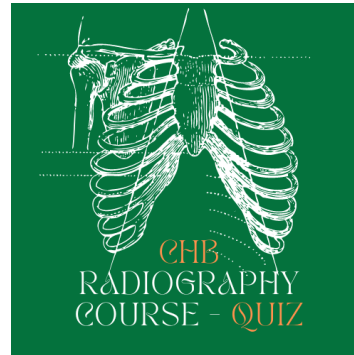


Module 9: CHB Radiography Quiz for Pelvis and Hip



1. Please fill in the blanks

Radiographic indications	Common Pathologies	AP Pelvis/Hip Radiographic positioning	Lateral Hip radiographic positioning
Early radiographic signs	<div>Femoracetabular Impingement<ul style="list-style-type: none">• Pincer Impingement• Cam impingement• Hip Dysplasia</div>		
Secondary radiographic signs	<div><ul style="list-style-type: none">• Labral tear</div>		
	<div><ul style="list-style-type: none">• OA</div>		
	<div><ul style="list-style-type: none">• Pathology that change texture of bone (e.g RA, avascular necrosis, osteoporosis)</div>		

Trauma	<ul style="list-style-type: none"> • Intracapsular fracture Head and neck of Femur) 		
	<ul style="list-style-type: none"> • Intertrochanteric fracture 		
	<ul style="list-style-type: none"> • Subtrochanteric Fracture 		
Post operation	<ul style="list-style-type: none"> • Cannulated screw 		
	<ul style="list-style-type: none"> • DHS 		
	<ul style="list-style-type: none"> • Hemiarthroplasty 		
	<ul style="list-style-type: none"> • THR 		
	<ul style="list-style-type: none"> • Femur Nail or LISS 		

2. Find a student/colleague, show them how to perform a Dunn view, and a 40 degree cranial lateral hip.