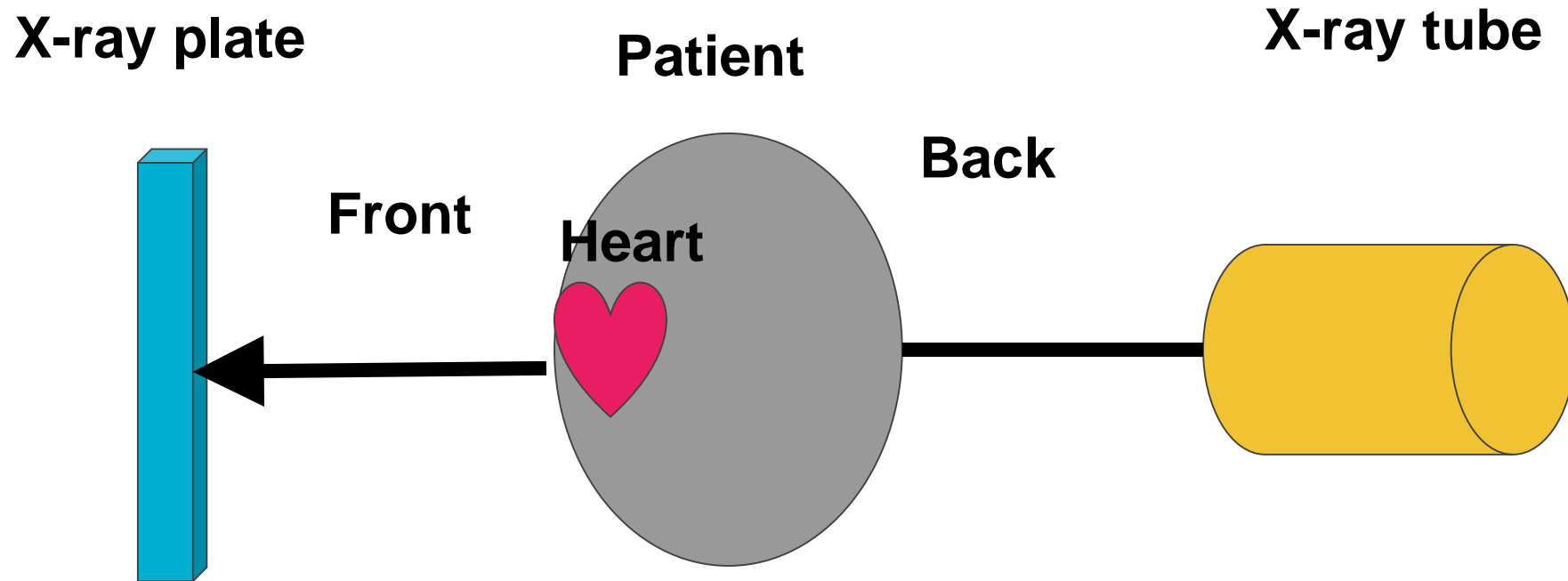
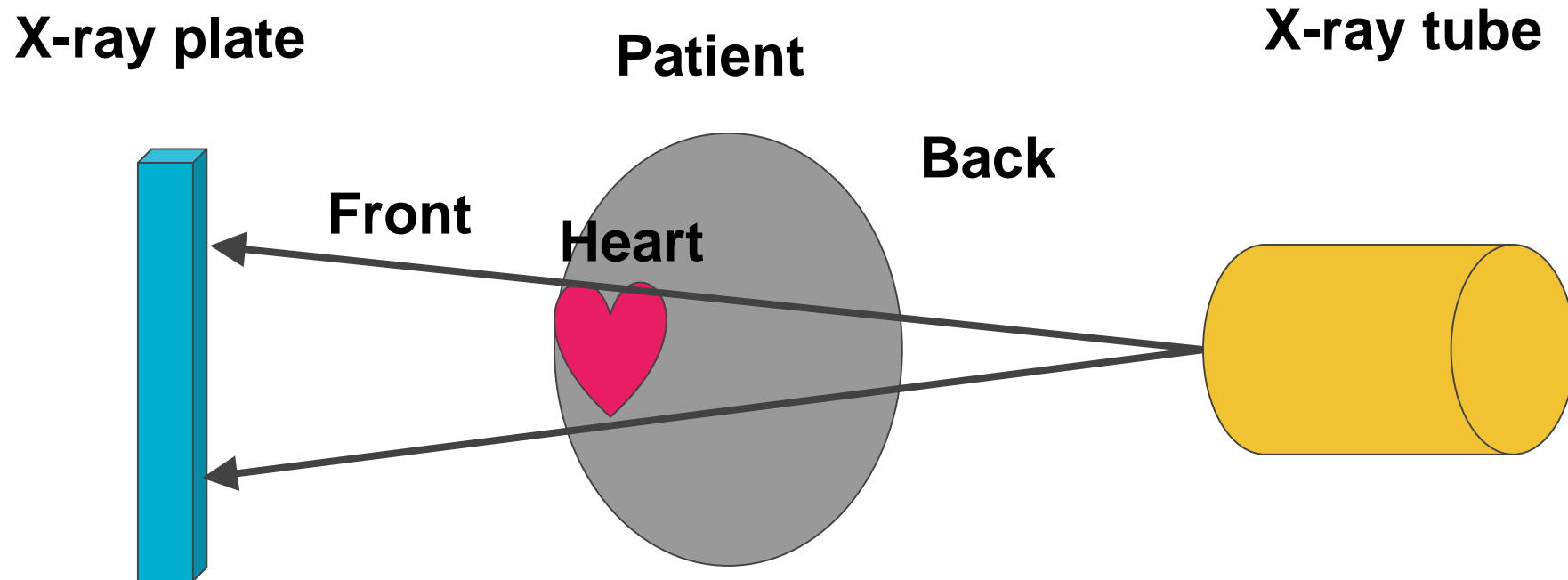

HOW A CHEST X RAY IS OBTAINED

How PA films are obtained



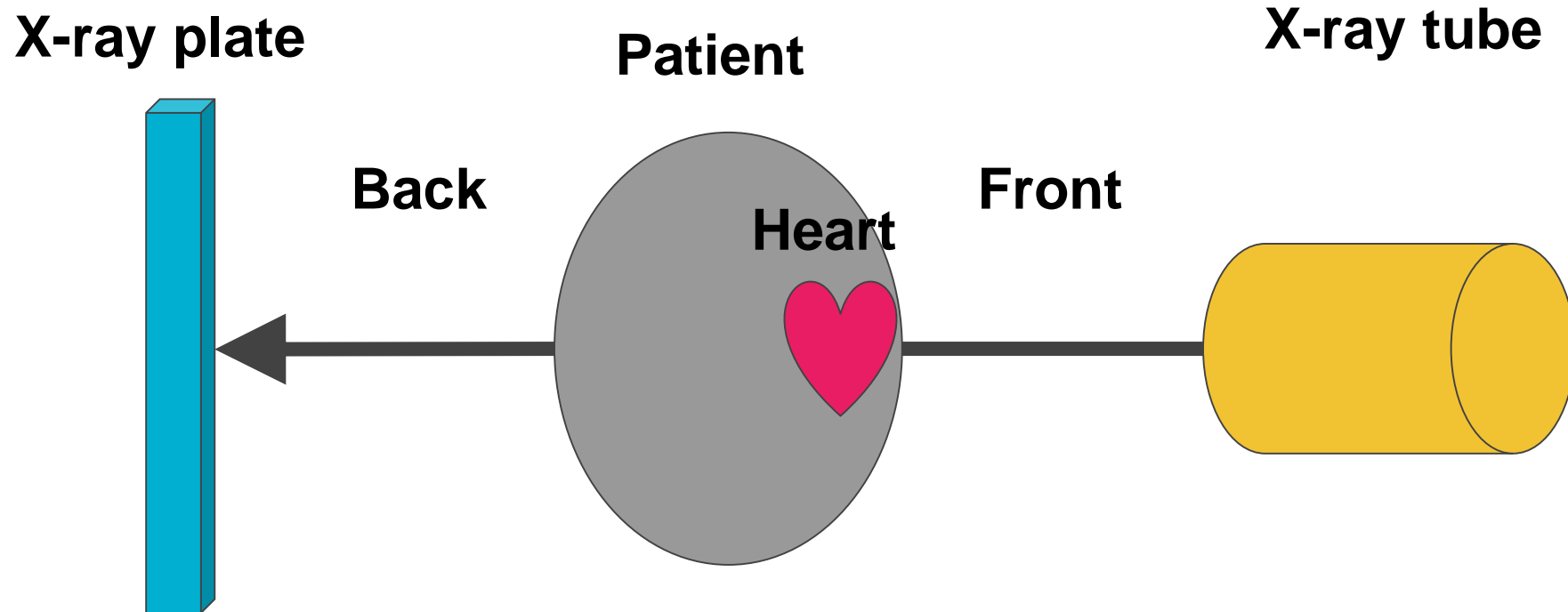
_____ film: The heart is closer to the x-ray plate so it appears smaller compared to the AP projection.

How PA films are obtained



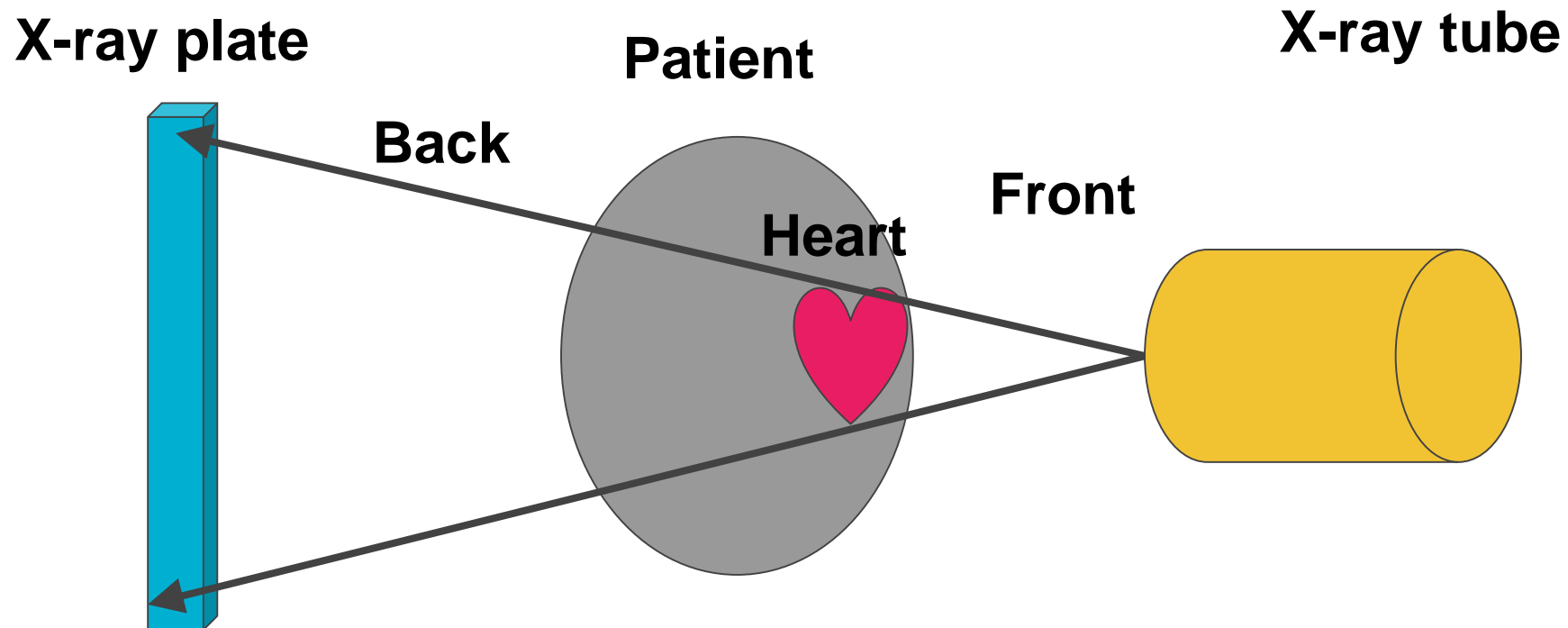
Posterior-Anterior (PA) film: The heart is closer to the x-ray plate so it appears smaller compared to the AP projection.

How AP films are obtained



Anterior-Posterior (AP) film

How AP films are obtained



_____ film: The heart is further from the plate so it appears larger on the image

Heart size on supine x-rays

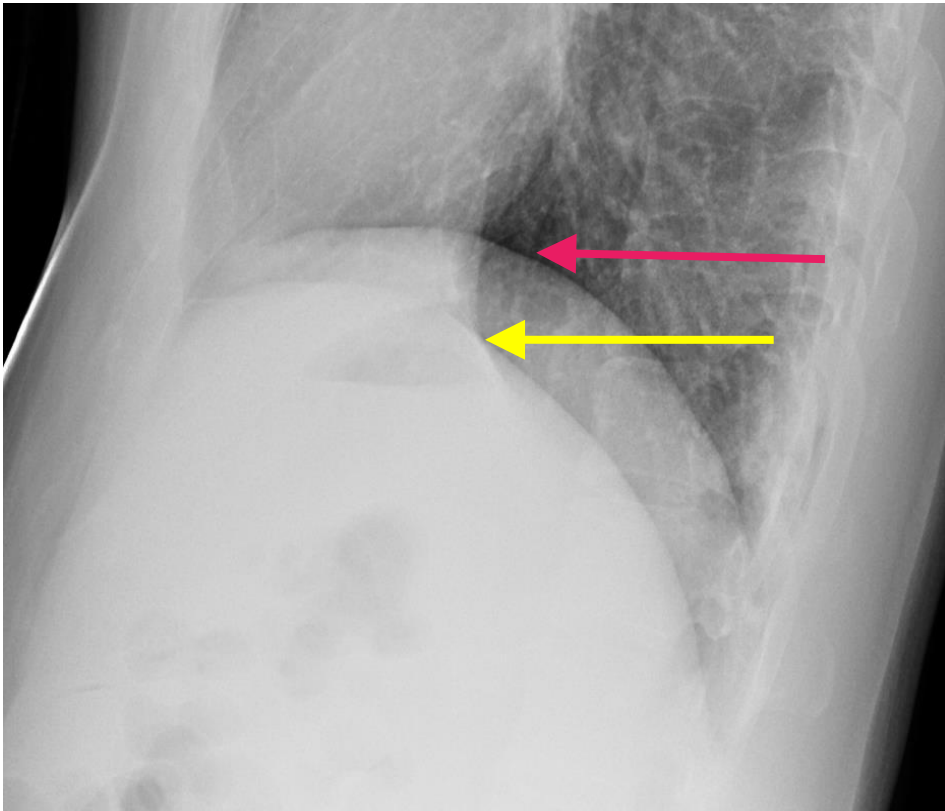
Most supine films are usually performed with _____ technique.

In addition, the heart usually spreads out more in the supine position thereby making the heart appear even larger.

How are lateral films obtained?

The lateral chest radiograph is performed with the ___ chest against the plate by convention. Consequently, the right diaphragm always appears slightly larger on the lateral view. It tends to extend the most posterior.

How are lateral radiographs obtained?



The right diaphragm (fuschia arrow) usually appears slightly higher on the lateral view.

We will review this further in the diaphragm section.

The heart is resting on the _____ diaphragm (yellow arrow).

What to do before you start reading a chest x-ray

Make sure you have the following items checked:

- The correct patient name
- The right date and time especially when serial exams are ordered.
- The right exam.
- It is important to get this step right otherwise the consequences could be devastating for the patient.

